

INCISOR TOOTH BREAKAGE, ENAMEL DEFECTS, AND PERIODONTITIS IN A DECLINING ALASKAN MOOSE POPULATION

R. Stimmelmayr^{1,2}, J.A.K. Maier³, K. Persons⁴, and J. Battig⁵

¹Community and Natural Resources Department, Tanana Chiefs Conference, 122 First Ave., Fairbanks, AK 99701, USA; ³Institute of Arctic Biology, University of Alaska Fairbanks, Fairbanks, AK 99709, USA; ⁴Division of Wildlife Conservation, Alaska Department of Fish & Game, Nome, AK 99762, USA; ⁵Chena Ridge Veterinary Clinic, Fairbanks, AK 99709, USA

ABSTRACT: We examined 56 anterior segments of mandibles from moose harvested from a declining population that was affected by tooth wear and breakage at higher rates than in moose elsewhere on the Seward Peninsula, Alaska. Incisor teeth were examined for extent of tooth wear and breakage, the degree and prevalence of surface enamel defects, and radiographic evidence of periodontitis. Body size (incisor arcade width of adult moose) and body condition index (timing of tooth eruption in yearlings) of the Seward Peninsula population were compared to other Alaskan moose populations. Mean (\pm SE) age of adult moose in the study was 4.6 ± 0.4 years. The age distribution of harvested moose was 32% yearling, 61% young adult (2-6 years old), 4% prime adult (7-11 years old), and 4% old moose (> 11 years old). Comparatively smaller body size in moose observed in this study probably reflects the absence of older animals in the 2002 harvest. Timing of tooth eruption in yearlings was within the range of other moose populations. Mean tooth wear and breakage score was 2.1 ± 0.2 . Ninety-three percent of the teeth exhibited hypoplastic enamel defects (pits) and staining, while 59% exhibited vertical and horizontal fracture lines on both labial and lingual tooth surfaces. Fifty-three percent of examined teeth showed radiographic signs consistent with periodontitis. Evidence of osteoporosis was present in 74% of the examined jaws. We hypothesize that observed enamel defects exacerbate age-related tooth wear and breakage in this population thereby resulting in accelerated demise of older animals. The skewed age distribution, with very few animals > 7 years supports this conclusion. The etiology of the observed enamel defects is unclear and requires further investigation.

ALCES VOL. 42: 65-74 (2006)

Key words: Alaskan moose, *Alces alces gigas*, mandibular bone loss, moose, periodontitis, tooth wear and breakage

Many rural residents in Alaska depend heavily on wild animals such as moose (*Alces alces*) for their meat supply. In the late 1980s the Alaska Department of Fish & Game began collecting general harvest data on the moose population; hunters were required to report sex, age, and location of kills and submit the distal portion of jaws from harvested moose on the Seward Peninsula. Department biologists found that the teeth were characterized by excessive breakage and wear (Smith 1992). The Seward Peninsula moose population has

been declining precipitously for more than 15 years, the cause(s) of which is unclear at this point. Digestive efficiency and animal productivity are dependent on oral health and tooth integrity such that a decline in chewing efficiency and body condition are associated with age-related tooth wear in cervids (*Rangifer tarandus*: Tyler 1986, Skogland 1988, Kojola et al. 1998; *Cervus Elaphus*: Perez-Barberia and Gordon 1998). Certainly the productivity of an ungulate population may be negatively affected by excessive tooth wear

²Present address: Ross University School of Veterinary Medicine, Department of Structure and Function; P.O. Box 334, Basseterre, St. Kitts, West Indies; rstimmelmayr@rossvet.edu.kn

and breakage. We report the extent of incisor tooth wear and breakage, degree of surface enamel defects, and prevalence of periodontitis in 56 anterior segments of moose mandibles submitted by hunters on the Seward Peninsula in 2002. We also compare estimated body size of Seward moose to moose of Interior Alaska using the distance between the buccal surfaces of canines (arcade width) in adult moose. In yearlings we used timing of tooth eruption as a proxy indicator of body condition.

STUDY AREA

The Seward Peninsula, Alaska, USA (Nome latitude 64° 25', longitude 165° 30'), is underlain by permafrost and is characterized by uplands of broad rounded hills and flat lowlands (USDA Forest Service, <http://www.fs.fed.us/colorimagemap/images/ml25.html>). Soils are poorly drained, and wetlands comprise 53 % of the area. There are many inland and coastal lakes and ponds. Vegetation includes moist-tundra, sedge-tussock meadows, sparse willows, birch, and isolated spruce-hardwood forests, particularly along rivers; while alpine-tundra heath-meadows and barrens dominate the high mountains. Climate is characterized by long, cold winters (average -24 to -19°C), and short, cool summers (+1 to +6°C), with heavy annual snowfall (1,000 to 2,000 mm) and rain (460 mm). Occurrence of wildfires is common, particularly from June through August. Human population is low and dispersed, with the largest settlement being Nome. Old and new mining enterprises exist throughout the region.

METHODS

Hunters submitted 56 anterior segments of moose mandibles (adults: 36 males, 2 females; yearlings: 17 males, 1 female) during the 2002 hunting season (August-September). These specimens were frozen at -10°C within 24 hours of collection and kept frozen for 5 months before analysis. A lower incisor was extracted in adult animals ($n = 38$) for

determination of age (Wolfe 1969). Age was estimated from tooth root annuli by Matson's Laboratory (Matson's Laboratory, LCC 2001; P.O. Box 308, Milltown, MT 59851, USA).

Body Size and Condition

We used incisor arcade width (the distance between the buccal surfaces of the incisiform canines, I_1) as a proxy of body size for adult moose. In moose, incisor arcade width is positively correlated to body mass (Spaeth et al. 2001). Arcade width was measured to the nearest 1 mm with a dial caliper (Spaeth et al. 2001). Lower jaws of adult female moose ($n = 2$) and jaws of juveniles with missing canines ($n = 3$) were not included in the analysis. Status of tooth eruption was determined in moose < 2 years. Timing of tooth eruption has been proposed to be linked to body condition in cervids (*Odocoileus hemionus*: Robinette et al. 1957; *Alces alces*: Peterson et al. 1983; *Cervus elaphus*: Loe et al. 2004). Individual teeth were described as missing, deciduous, erupting, or permanent.

Tooth Wear and Breakage

Individual mandibular incisors were examined under artificial light. Anterior segments of adult moose mandibles were grouped according to tooth wear and breakage as described by Smith (1992). Briefly, individual incisor teeth were scored on a scale of 1-5 for wear and breakage (Class 1: < 15% of crown missing; Class 2: 15-25% of crown missing; Class 3: 25-35% crown missing; Class 4: 35-50% crown missing; Class 5: > 50% crown gone, root canal exposed).

Macro-Enamel Defects

Both enamel tooth surfaces, lingual, the surface facing the tongue, and labial, the surface facing the lip, were macroscopically examined for staining, fracture lines, and differences in enamel thickness (enamel hypoplasia) such as pits, vertical and horizontal furrows, and plane defects (Goodman and

Rose 1990, 1991). Teeth were classified as normal, pitted, or sprinkled, and percentage of tooth area pitted and stained (< 10, 11-30, 31-50, 51-75, 76-100%) was recorded. A normal tooth showed smooth, translucent, glossy white enamel; a pitted tooth had white surface enamel with multiple, randomly distributed pits; a sprinkled tooth had a discrete and subtle appearance of uniformly scattered, brown-black staining and discrete pits; and Class 10-100% described the extent of discrete pitting and confluent staining in relation to total crown surface.

Periodontitis

Radiographs were taken of 37 adult jaws (36 males; 1 female) (Transworld® 325 V) to determine prevalence of periodontitis (Huunonen and Orstavik 2002). Mandibles were placed directly onto film cassettes (Kodak® Clinic Select x-ray film, regular speed green 35 x 43 cm) to maximize accuracy and sharpness of x-rays. Right and oblique angle views were taken of each jaw (50 kV and 300 mA). Changes of alveolar bone were recorded for each tooth. Width and height of radiolucent lesions (areas of bone loss as indicated by decreased radiodensity) were measured with a ruler to the nearest 1 mm and then categorized according to their specific location (i.e., root end opening, alongside the root). Occurrence of root caries was assessed and root length, distance between cemento-enamel junction and root tip, was measured (mm). Mandibular bone loss was assessed qualitatively by scoring general radiolucency (absent, mild, moderate, and severe). We initially measured pocket depth and recession using a standard dental probe on individual teeth to detect periodontitis. Notwithstanding, we eventually excluded these measurements from our analysis because the mandibles had gone through repeated freezing and thawing during the examination and this may have affected gum recession and pocket depth. We also did not assess tooth mobility (indicator of periodontal disease). Restricted

tooth movement in ruminants is normal due to the low alveolar crest height (Nickel et al. 1973). Finally, we documented the presence and absence of impacted food.

Statistical Analysis

One-tailed *t*-tests were used to compare differences between means. We assumed independence of contra-lateral teeth (Perzigian 1977) and therefore did not apply a Bonferroni correction for comparison of contra-lateral incisiform measurements. Data were examined for unequal variance using *F*-test for unequal variances prior to conducting *t*-tests. Statistical software used was Analysis ToolPack (®Microsoft Excel, Version 2000). Significance was assessed at the $\alpha = 0.05$ level. Data are reported as means \pm SE.

RESULTS

Mean (\pm SE) age of adult moose in the study was 4.6 ± 0.4 years. The age distribution of harvested moose was 32% yearling ($n = 18$), 61% young adult (2-6 years old; $n = 34$), 4% prime adult (7-11 years old; $n = 2$), and 4% old moose (> 11 years old; $n = 2$). No food impaction was present in the examined jaws.

Body Condition and Body Size

Tooth eruption pattern of yearlings is summarized in Table 1. Left Incisor 2 was fully erupted in 50% ($n = 9$) of the jaws examined, while the right incisor 2 was fully erupted in only 39% ($n = 7$). Mean incisor arcade width for male adults (5.75 ± 0.04 cm) was greater than that for male yearlings (4.69 ± 0.06 cm; $t = 15.43$; 49 df, $P < 0.0001$).

Table 1. Eruption status of dentition (left; right) in yearling ($n = 18$) moose of the Seward Peninsula, Alaska, 2002.

Dentition	Incisor 1	Incisor 2	Incisor 3	Incisor 4
Permanent	18;18	9;7	0	0
Erupting	0	3;6	1;0	0
Deciduous	0	6;5	17;18	18;15
Missing	0	0	0	0;3

Table 2. Distribution of labial and lingual surface fracture lines of incisors in moose of the Seward Peninsula, Alaska, 2002.

Location	Incisor 1 (L, R)	Incisor 2 (L, R)	Incisor 3 (L, R)	Incisor 4 (L, R)
Labial & Lingual	41, 35	38, 36	22, 23	3, 3
Lingual	1, 2	0, 1	10, 12	22, 21
Labial	3, 4	0, 1	0, 0	0, 0
None	8, 11	5, 6	4, 3	12, 12

Tooth Wear and Breakage

Short, shovel-like crowns with distinct necks and thick roots characterized permanent incisor teeth. Mean (\pm SE) tooth wear and breakage score was 2.1 ± 0.2 . Classification of examined jaws by tooth wear and breakage was unbroken (18%; $n = 7$), Class 1 (18%; $n = 7$), Class 2 (21%; $n = 8$), Class 3 (26%; $n = 10$), Class 4 (8%; $n = 3$), and Class 5 (5%; $n = 2$). An example of irregular incisor tooth wear and breakage with multiple lingual and labial surface fracture lines, tooth staining, and partially missing crowns is depicted in Figure 1.

Fracture Lines and Hypoplastic Enamel Defects

Data on labial and lingual surface fracture lines are summarized in Table 2. Both labial and lingual fracture lines on the same tooth were present in 59% ($n = 201$) of examined teeth ($n = 339$), with I_4 having the least (Table 2). Fracture lines were absent in 18% ($n = 61$) of examined incisors. Yearlings were the dominant age group without fracture lines (Left (L) = 75%; $n = 13$; Right (R) = 91%; $n = 16$) for I_1 ; (L = 40%; $n = 4$; R = 91%; $n = 6$) for I_2 ; the one yearling who had an I_3 contained no fractures in that tooth; no yearlings had an I_4 , as their incisiform canines had not emerged. All teeth had varying degrees of staining and pitting (Table 3). Sixty percent of examined teeth had $\geq 50\%$ ($n = 199$) pitting and discoloration of the total tooth surface enamel. No tooth discoloration and pitting was present in

4% ($n = 15$) of the teeth and 3% ($n = 11$) had pitting with no stains.

Periodontitis

Fifty-three percent of incisors ($n = 140$) had radiolucent lesions (Table 4; Fig.2), and 84 % ($n = 117$) of these were at the root end opening (Table 4). Mean (\pm SE) radiolucent area ranged between 13.3 ± 2.5 and 58 ± 21 mm² (Table 5). Total radiolucent area was not different between contralateral incisors (Table 5) as were root length (Table 5). Root caries was present in 13% ($n = 32$) of examined incisors (Table 4). Seventy-four percent of examined jaws exhibited signs of osteoporosis. Distribution of osteoporosis scores of examined jawbones ($n = 34$) was: absent ($n = 9$), mild ($n = 11$), moderate ($n = 10$), and severe ($n = 4$).

DISCUSSION

Mean age of the 2002 harvested animals fell within the range of mean age of moose harvested on the Seward Peninsula in previous years (3.1 ± 0.3 to 5.1 ± 0.4 ; Stimmelmayer and Maier, unpublished data). The skewed age distribution of harvested moose however,

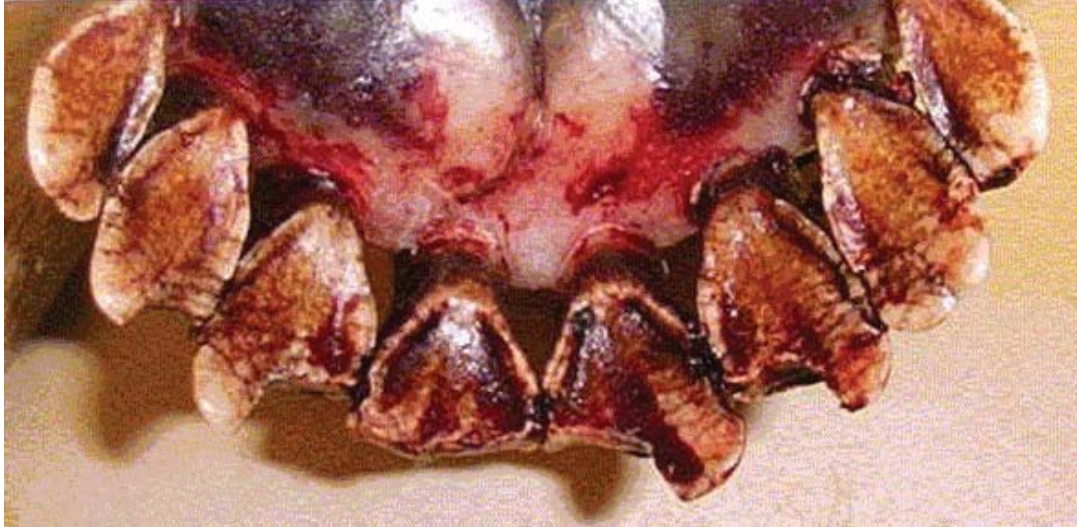Table 3. Distribution of degree of staining and pitting of incisiform teeth in moose on the Seward Peninsula, Alaska, 2002.

Tooth Staining & Pitting	Incisor 1 (L, R)	Incisor 2 (L, R)	Incisor 3 (L,R)	Incisor 4 (L,R)
Normal	0,0	2, 4	2,3	2,2
Pitted ¹	0,0	2, 1	2,2	2,2
Sprinkled ²	17,16	4, 7	3,4	3,4
≤ 10	4,5	1,0	1,1	2,2
11-30	5,5	4, 2	5,3	6, 6
31-50	22,21	11, 14	10,6	14,9
51-75	3,4	13,9	11,15	5,9
76-100	1,0	5, 7	2,4	2, 2

¹ A pitted tooth demonstrated white surface enamel with multiple, randomly distributed pits.

² A sprinkled tooth had a discrete and subtle appearance of uniformly scattered brown-black staining and discrete pits.

Fig.1. Incisor teeth (lingual view) with lingual-labial enamel fracture lines extending netlike over the entire crown surface and individual irregularly shaped teeth with sharp angles and contours in a young adult moose on the Seward Peninsula, Alaska, 2000. The mean tooth wear score (\pm SE) for this animal is 2.25 ± 0.73 .



indicates a young population with animals > 7 years old missing, suggesting decreased survivorship of older animals. Over the last 10 years (1991-2001), percentage of harvested prime moose has decreased by about half while percentage of harvested young adult moose has increased (Maier, unpublished data), lending support to this hypothesis. Mean, incisor-arcade width for adult males was 5.75 ± 0.04 cm and fell within the lower range of reported values for Alaskan moose (5.7 – 6.1 cm; Spaeth et al. 2001). Yearlings had significantly smaller incisor width than did adults. A similar finding was demonstrated by Spaeth et al. (2001) where the incisor-arcade width increases with age and finally stabilizes in both sexes of Alaskan moose at their ultimate size. Arcade width in moose is strongly correlated to body mass; we hypothesize that the small body size probably reflects the predominantly young age distribution in the 2002 harvest, although reduction in body size and low recruitment are well-known density-related trade-offs in moose populations (Ferguson et al. 2000). The small body size of moose in our study may be due to density dependence, although the moose population on the Seward

Peninsula is thought to be below the current carrying capacity of the habitat. Data regarding moose habitat on the Seward Peninsula is lacking. Timing of the eruption of Incisor 2 was highly variable (50%) but comparable to other free-ranging Alaskan moose populations from the Kenai Peninsula and Nelchina Basin (Peterson et al. 1983). Hence, our data on

Table 4. Frequency and specific location (root end opening and alongside the root) of radiolucent lesion and associated root caries in moose on the Seward Peninsula, Alaska, 2002.

Variable	Incisor 1 (L, R)	Incisor 2 (L, R)	Incisor 3 (L, R)	Incisor 4 (L, R)
Radiolucent lesion				
Present	28,26	18,14	13,19	11,11
Absent	6,7	17,19	20,14	21, 22
Specific Location				
Root end opening	18,22	16,12	11,17	10,11
Alongside the root	10,4	2,2	2,2	1,0
Root caries ¹				
Absent	17,18	18,20	19,20	25,28
Present	8,10	3,2	3,4	2,0
Fuzzy	7,6	13,11	9,6	4,3

¹Five (L) and six (R) could not be evaluated for root caries.

Table. 5. Mean (\pm SE) radiolucent lesion area (mm^2)¹ and root length (mm) of incisiform teeth categorized by side of mouth in moose on Seward Peninsula, Alaska, 2002.

Teeth	Left	Right	Statistics
Incisor 1			
Radiolucent lesion (mm^2)	34 ± 8	58 ± 21	$t = -1.07, 31 \text{ df}, P = 0.15$
Root length (mm)	35.6 ± 0.7	35.9 ± 0.6	$t = -0.2, 68 \text{ df}, P = 0.39$
Incisor 2			
Radiolucent lesion (mm^2)	17.09 ± 3.8	49.06 ± 30.07	$t = -1.02, 8 \text{ df}, P = 0.17$
Root length (mm)	35.2 ± 0.6	35.3 ± 0.6	$t = -0.16, 67 \text{ df}, P = 0.44$
Incisor 3			
Radiolucent lesion (mm^2)	19.7 ± 3.5	28.4 ± 13.2	$t = -0.64, 17 \text{ df}, P = 0.26$
Root length (mm)	33.3 ± 0.6	33.4 ± 0.7	$t = -0.14, 67 \text{ df}, P = 0.45$
Incisor 4			
Radiolucent lesion (mm^2)	13.3 ± 2.5	13.7 ± 5.5	$t = -0.07, 9 \text{ df}, P = 0.47$
Root length (mm)	32.1 ± 0.6	33.1 ± 0.6	$t = -1.14, 66 \text{ df}, P = 0.13$

¹ Width and height of radiolucent lesions were measured with a ruler to the nearest 1 mm.

tooth eruption do not support the notion of a decline in body condition in yearling moose on the Seward Peninsula. Nonetheless, the genetic influence on timing of tooth eruption is considerable and may limit interpretation when comparing among moose populations (Peterson et al. 1983, Loe et al. 2004).

Mean tooth wear and breakage score 2.1 ± 0.2 was lower than scores from previous years (2.6 ± 0.3 to 3.9 ± 0.4 ; Stimmelmayer and Maier, unpublished data). Fewer animals, however, had zero breakage with 18.4% in this study compared to 29% in 1999. Density dependence, mineral content of soil, and typical moose feeding behavior close to the ground are all factors that have been implicated as possible causes in age-related tooth wear for different moose populations (Smith 1992). Incisiform tooth wear and breakage in our population differs from the age-related tooth wear observed in other Alaskan moose populations (Stimmelmayer and Maier, unpublished data). Moose incisor tooth wear on the Seward Peninsula is characterized by individual irregularly shaped teeth with sharp angles and contours (Fig.1), with lingual-labial enamel fracture lines extending netlike over the entire crown surface. In contrast, incisors from Alaskan

moose from Kalgin Island are characterized by smooth labial and lingual surface enamel with even wear on all incisors (Fig. 3), while incisors from Tanana Flats are characterized by smooth labial and lingual surface enamel with marked interproximal U-shaped wear (Fig. 4.); lingual-labial surface fracture lines are singular and vertically oriented. Tooth conditions similar to moose from the Tanana

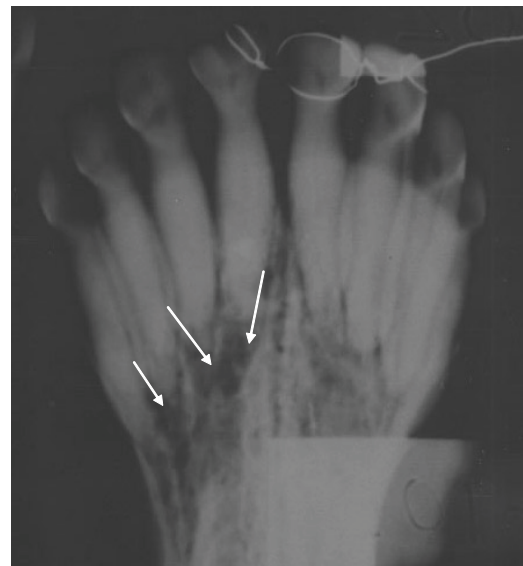

Fig.2. Radiographic example of several periodontal lesions (arrows L: Incisor 1, 2, and 3) in moose on the Seward Peninsula, Alaska, 2002.




Fig. 3. Incisor teeth (labial view) with smooth labial and lingual surface enamel and even wear on all incisors in moose on Kalgin Island, Alaska, 2002.

Flats have been described in Canadian moose from Manitoba (Young and Marty 1986). We hypothesize that the degree and extent of enamel defects exacerbate age-related tooth wear and breakage in our population. Reduction of hardness and elasticity of hypoplastic enamel in comparison to normal enamel has been observed in humans (Mahoney et al. 2004). Development of enamel defects has been related to exposure to a variety of physiological stresses (i.e., disease, malnutrition) during the enamel formation period (Goodman and Rose, 1990, 1991). The underlying etiology of enamel defects observed in our study is unclear and requires further investigation.

The majority of examined teeth had both lingual and labial surface fracture lines (59%), while only 18% of all teeth had neither. Lingual fractures probably precede labial ones based on the distribution pattern of fracture lines for all incisors (Table 3). The observed difference in enamel thickness on the lingual surface (thinner) in ruminants may be responsible for our observation (Miles and Grigson 1990). Brown tooth discoloration and pitting were prevalent with only 4% of teeth having no staining at all and 3% having no stains, but pitting (Table 3). In contrast to domestic ruminants (Nickel et al. 1973), tooth surface fracture lines and brown tooth staining are considered to be typical in adult moose incisors. The consumption of

tannin rich forage is most likely the cause of the brown-black discoloration suggested for humans and laboratory animals (Nordbo 1977, Nordbo et al. 1982).

Periodontitis can play a key role in exacerbating tooth wear and premature tooth loss, as well as compromise animal health due to systemic illness (Aitchison and Spence 1984, Debowes 1998, Gorrel 1998, Duncan et al. 2003). Fifty-three percent of teeth had lesions consistent with periodontitis. Periodontitis, affecting premolar and molar, is frequently reported in captive bovids and free-ranging moose (Peterson et al. 1982), and other ruminants (Miles and Grigson 1990), and has been linked to food impaction and associated soft-tissue injury (Miles and Grigson 1990). No signs of food impaction were found in our study. Interestingly, root caries were present in only 13% of teeth, despite the high prevalence of periodontitis.

Seventy-four percent of the examined jaws exhibited signs of osteoporosis of the mandibular bone. Osteoporotic circular skull-lesions and periodontal lesions associated with molars have been previously reported in moose on Isle Royale (Hindelang and Peterson 1993, 1996, 2000). Osteoporotic lesions were absent in Isle Royale moose younger than 7 years, but increased with age. Males in that study had a higher prevalence of lesions than

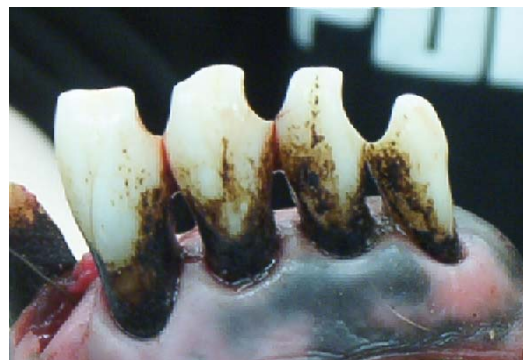

Fig.4. Incisor teeth (labial view) with smooth labial and lingual surface enamel and distinct interproximal U-shaped wear in moose from the Tanana Flats, Alaska, 2002.

did females. The prevalence rate of 32% in Isle Royale moose was considerably lower than we found (74%). Metabolic stressors (e.g., antler growth, gestation, and lactation) have been implicated as potential causative factors for osteoporosis in Isle Royale moose (Hindelang and Peterson 1993, 1996, 2000), while environmental exposure to heavy metals (lead) is thought to play a role in the increased incidence of osteoporosis in moose in Norway (Bjora et al. 2001). Alternative explanations for the increased rate of bone loss include inbreeding and a founder effect (Recker and Deng 2002, Seeman 2003).

In conclusion, our findings indicate that tooth wear and breakage, periodontitis, hypoplastic enamel defects, and mandibular bone loss are common in moose of the Seward Peninsula. Percentage of moose jaws affected by osteoporosis exceeds what is reported for moose on Isle Royale, Michigan. It is unclear at this point whether periodontitis, mandibular bone loss, and tooth wear and breakage are related, but it is highly likely. Independent of underlying etiological mechanisms (i.e., nutrition, health, genetics, trace metal deficiency, heavy metals) of the complex dental pathology in moose on the Seward Peninsula, we hypothesize that the degree and extent of enamel defects exacerbate their age-related tooth wear and breakage, thereby resulting in accelerated mortality in older animals > 7 years. The skewed age distribution in our harvest lends support to this hypothesis.

ACKNOWLEDGEMENTS

This work was funded in part by a grant from the U.S. Bureau of Indian Affairs (BIA). We are indebted to the residents of the Seward Peninsula for their continued interest, involvement, and willingness to provide us with samples via the Alaska Department of Fish & Game. We thank Drs. R.T. Bowyer, K.J. Hundertmark, V. Van Ballenberg for reviewing an earlier draft of this manuscript, and the anonymous reviewers, who greatly improved

the quality of the final manuscript. We thank M. Sullivan for expert editing.

REFERENCES

- AITCHISON, G.U., and J.A. SPENCE. 1984. Dental disease in hill sheep: an abattoir survey. *Journal of Comparative Pathology* 94: 285-300.
- BJORA, R., J. A. FALCH, H. STAALAND, L. NORDSLETTEN, and E. GJENGEDAL. 2001. Osteoporosis in the Norwegian moose. *Bone* 29: 70-73.
- DEBOWES, L. J. 1998. The effects of dental disease on systemic disease. *Veterinary Clinic North America Small Animal Practice* 28: 1057-1062.
- DUNCAN, W. J., G. R. PERSSON, T. J. SIMS, P. BRAHAM, A. R. PACK, and R. C. PAGE. 2003. Ovine periodontitis as a potential model for periodontal studies. Cross-sectional analysis of clinical, microbiological, and serum immunological parameters. *Journal of Clinical Periodontology* 30: 63-72.
- FERGUSON, S., A. R. BISSET, and F. MESSIER. 2000. The influences of density on growth and reproduction in moose *Alces alces*. *Wildlife Biology* 6: 32-39.
- GOODMAN, A. H., and J. C. ROSE. 1990. Assessment of systemic physiological perturbations from dental enamel hypoplasias and associated structures. *Yearbook of Physical Anthropology* 33: 59-110.
- _____, and _____. 1991. Dental enamel hypoplasias as indicators of nutritional stress. Pages 279-293 in M. A. Kelley and C. S. Larson, editors. *Advances In Dental Anthropology*. Wiley-Liss Incorporated, New York, New York, USA.
- GORREL, C. 1998. Periodontal disease and diet in domestic pets. *Journal of Nutrition* 128(12 Supplement): 2712S-2714S.
- HINDELANG, M., and R. O. PETERSON. 1993. Relationship of mandibular tooth wear to gender, age and periodontal disease of Isle Royale moose. *Alces* 29: 63-73.
- _____, and _____. 1996. Osteoporotic skull

- lesions in moose at Isle Royale National Park. *Journal of Wildlife Diseases* 32: 105-108.
- _____, and _____. 2000. Skeletal integrity in moose at Isle Royale National Park: bone mineral density and osteopathology related to senescence. *Alces* 36: 61-68.
- HUUMONEN, S., and D. ORSTAVIK. 2002. Radiological aspects of apical periodontitis. *Endodontic Topics* 1: 3-25.
- KOJOLA, I., T. HELLE, E. HUHTA, and A. NIVA. 1998. Foraging conditions, tooth wear and herbivore body reserves: a study of female reindeer. *Oecologia* 117: 26-30.
- LOE, L. E., E. L. MEISINGSET, Ø. A. MYSTERUD, R. LANGVATN, and N. C. STENSETH. 2004. Phenotypic and environmental correlates of tooth eruption in red deer (*Cervus elaphus*). *Journal of Zoology, London* 262: 83-89C.
- MAHONEY, E. K., F. S. M. ISMAIL, N. KILPATRICK, and M. SWAIN. 2004. Mechanical properties across hypomineralized/hypoplastic enamel of first molar teeth. *European Journal of Oral Science* 112: 497-502.
- MILES, A. E. W., and C. GRIGSON. 1990. *Colyer's Variations and Diseases of the Teeth of Animals*. Revised edition. University Press, Cambridge, U.K.
- NICKEL, R., A. SCHUMMER, E. SEIFERLE, and W. O. SACK. 1973. Teeth. Pages 75-97 in E. Seiferle, editor. *The Viscera of the Domestic Mammals*. Verlag Paul Parey-Springer Verlag, Berlin, Germany.
- NORDBO, H. 1977. Discoloration of dental pellicle by tannic acid. *Acta Odontologica Scandinavica* 35: 305-310.
- _____, H. M. ERIKSEN, G. ROLLA, A. ATTRAMADAL, and H. SOLHEIM. 1982. Iron staining of the acquired enamel pellicle after exposure to tannic acid or chlorhexidine: preliminary report. *Scandinavian Journal of Dental Research* 90: 117-123.
- PEREZ-BARBERIA, F. J., and I. J. GORDON. 1998. The influence of molar occlusal surface area on the voluntary intake, digestion, chewing behavior and diet selection of red deer (*Cervus elaphus*). *Journal of Zoology* 245: 307-326.
- PERZIGIAN, A. J. 1977. Fluctuating dental asymmetry: variation among skeletal populations. *American Journal of Physiological Anthropology* 47: 81-88.
- PETERSON, R. O., J. M. SCHEIDLER, and P. W. STEPHENS. 1982. Selected skeletal morphology and pathology of moose from the Kenai Peninsula, Alaska and Isle Royale, Michigan. *Canadian Journal of Zoology* 60: 2812-2817.
- _____, C. C. SCHWARTZ, and W. B. BALLARD. 1983. Eruption patterns of selected teeth in three North American moose populations. *Journal of Wildlife Management* 47: 884-888.
- RECKER, R. R., and H. W. DENG. 2002. Role of genetics in osteoporosis. *Endocrine* 17: 55-66.
- ROBINETTE, W. L., D. A. JONES, G. ROGERS, and J. S. GASHWILER. 1957. Notes of tooth development and wear for Rocky Mountain mule deer. *Journal of Wildlife Management* 21: 134-153.
- SEEMAN, E. 2003. Invited Review: Pathogenesis of osteoporosis. *Journal of Applied Physiology* 95: 2142-2151.
- SKOGLAND, T. 1988. Tooth wear by food limitation and its life history consequences in wild reindeer. *Oikos* 51: 238-242.
- SMITH, T. E. 1992. Incidence of incisorform tooth breakage among moose from the Seward Peninsula, Alaska, USA. *Alces Supplement* 1: 207-212.
- SPAETH, D. F., K. J. HUNDERTMARK, R. T. BOWYER, P. S. BARBOZA, T. R. STEPHENSON, and R. O. PETERSON. 2001. Incisor arcades of Alaskan moose: is dimorphism related to sexual segregation? *Alces* 37: 217-226.
- TYLER, N. J. C. 1986. The relationship between the fat content of Svalbard reindeer in autumn and their death from starva-

- tion in winter. Rangifer Special Issue 1: 311–314.
- WOLFE, M. L. 1969. Age determination in moose from cementum layers of molar teeth. Journal of Wildlife Management 33: 428-431.
- YOUNG, G. Y., and T. M. MARTY. 1986. Wear and microwear on the teeth of a moose (*Alces alces*) population in Manitoba, Canada. Canadian Journal of Zoology 64: 2467-2479.