

USING PELVIS MORPHOLOGY TO IDENTIFY SEX IN MOOSE SKELETAL REMAINS

Jason A. Duetsch^{1,3} and Rolf O. Peterson²

¹Department of Fish, Wildlife, and Conservation Biology, Colorado State University, Fort Collins, Colorado 80523-1474, USA; ²School of Forest Resources and Environmental Science, Michigan Technological University, Houghton, Michigan 49931, USA.

ABSTRACT: The only published method for sex determination in even-toed ungulates (i.e., Cervidae) through the use of skeletal remains (excluding the skull) is pelvic suspensory tuberosity presence/absence in white-tailed (*Odocoileus virginianus*) and black-tailed deer (*Odocoileus hemionus columbianus*). Tuberosities are not easily distinguishable on moose (*Alces alces*) pelvises, even when a large number are available for comparison. Unlike in horses (*Equus caballus*) with similar skeletal structure as moose, pelvic inlets of moose show no distinctive sex characteristics on an individual level. Several linear angular (n = 5) and linear (n = 3) measurements were made on Isle Royale moose pelvises (n = 35). Results showed statistically significant differences between male and female pelvises for all angles, with unambiguous data collected from the angle created by the ischiatic arch (ventral brim of the ischium). As a rule of thumb, males and females exhibit an ischiatic arch angle of <90° and >90°, respectively. Two of the length measurements were also statistically different; however, overlap of these measurements would prevent their practical use. Learning more about sexing techniques will increase our forensic, archeological, and anatomical knowledge of moose anatomy and benefit sex determination in the field when only headless, scavenged, or partial carcasses remain.

ALCES VOL. 48: 1-6 (2012)

Key words: *Alces alces*, anatomy, moose, pelvis, Isle Royale, sex, tuberosity, ungulate, ischiatic arch.

Taber (1956) provides a method to determine sex of Cervidae from skeletal remains excluding the skull for white-tailed (*Odocoileus virginianus*) and black-tailed (*O. hemionus columbianus*) deer. Remains of males (>2 years old) are distinguished from those of females by the presence of tuberosities where ligaments attach that support the penis. These tuberosities are small bony projections found on the caudal border of the ischium bone of the pelvis (Fig. 1).

Tuberosities are not easily distinguishable on moose (*Alces alces*) pelvises, even when a large number of pelvises are available for comparison. We found that college undergraduate students (n = 9) correctly identified the sex of moose from its pelvis in only 61% of trials

(n = 15), despite training that included diagrams (Taber 1956) and examining tuberosities on moose pelvises. This problem is frequently compounded when pelvises originate from wolf-killed or scavenged carcasses that may have significant chewing and/or other deterioration on the posterior end of the pelvis where tuberosities are located.

Other techniques attempted with white and black-tailed deer include an assessment of the general shape of the pubic symphysis. Todd and Todd (1938) described the sexual distinction as the male showing a symphyseal face bi-convex in outline and the female having an outline concave ventrally and convex dorsally. Edelman (1943) stated similarly: "On the pubic symphysis the pelvis of the

³Colorado Division of Wildlife, 6060 Broadway, Denver, CO 80216, email: jason.duetsch@state.co.us

Suspensory Tuberosities

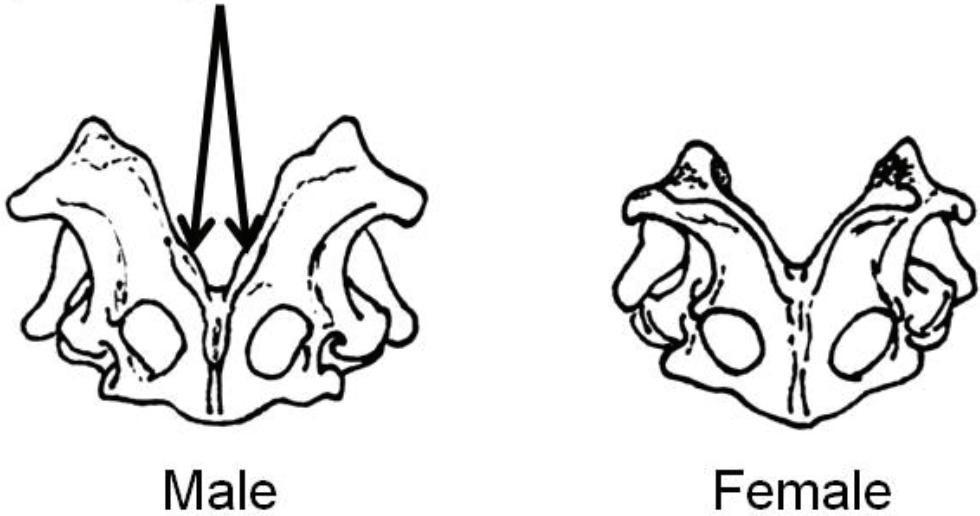


Fig. 1. Pelvic girdle of the white-tailed deer, viewed from the rear, showing the suspensory tuberosities for the attachment of the penis ligaments in the male and their absence in the female (after Taber 1956).

buck is thick and like a protuberance; that of the doe is thin, flat in front and slightly hollowed.” However, this technique requires that the pelvis in question be sawed in half along the pubic symphysis.

In species with a somewhat similar skeletal structure to moose (e.g., horses [*Equus caballus*]), detailed anatomical information exists which suggests that there are significant observable differences between male and female pelvises. Dyce et al. (2002) describe how the horse pelvic inlet of females, when viewed from the front of the pelvis, is wide and rounded while that of the male is more angular and cramped, particularly ventrally. In both sexes, the outlet from the pelvic cavity is much smaller than the inlet. The difference is so noticeable in cattle and sheep that one can determine the sex of carcasses from which all other identifying organs or structures have been removed (Bone 1988). However, a view of the pelvic inlet of moose shows no distinctive sex characteristics on an individual level and no published data exists for moose which states otherwise. For example, a sample may show adult male pelvises with larger pelvic

inlets than females or vice versa. The same is true when observing the overall space (a characteristic not easily quantified in moose) of the canal formed by the 2 halves of the pelvis.

The purpose of this study was to assess and develop a useful technique to identify sex of moose from pelvis characteristics. Such a technique would have forensic, archeological, and anatomical applications.

METHODS

Pelvises from moose of known sex were collected in 2003 from Isle Royale National Park (48°N, 89°W) under permit from the United States National Park Service as part of a study of wolf-moose ecology (Peterson 1977). Isle Royale includes 544 km² of natural habitat that supports moose at a density of 1-2/km².

Several linear angular ($n = 5$) and linear ($n = 3$) measurements were made (Fig. 2). All angles had their vertex along the pubic symphysis. Angle 1 is the ischiatic arch (ventral brim of the ischium), angle 2 is the inside of the lesser sciatic notch, and angle 3 is the

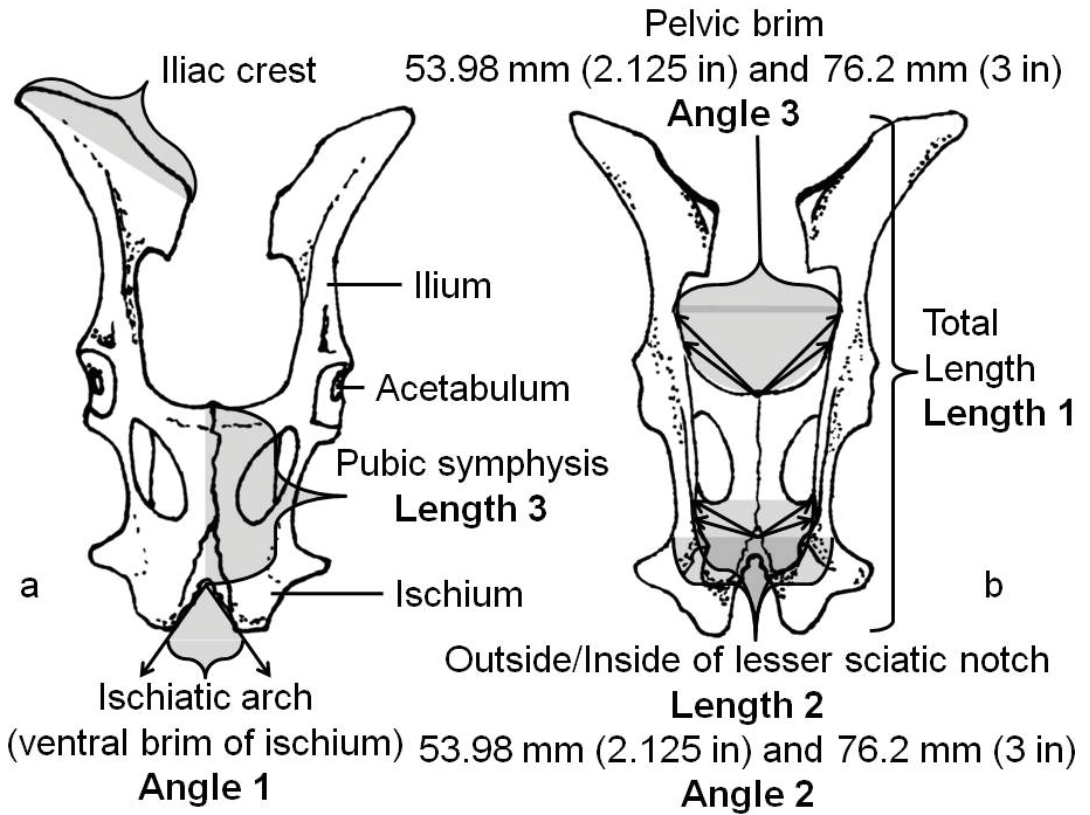


Fig. 2. Moose pelvis anatomy with lengths and angles 1, 2, and 3 from (a) ventral view and (b) dorsal view.

pelvic brim. Angles 2 and 3 were measured twice, first with vector lengths of 53.98 mm (2.125 in) from the vertex to the first point of contact, then with vectors of 76.2 mm (3.0 in) from the vertex to the first point of contact. The length measurements evaluated were total length, length of pubic symphysis, and outside width at the lesser sciatic notch. Our initial hypothesis was that significant differences between sexes would exist for all 8 measurements.

Pelvises from 17 male and 18 female moose >2 years old (confirmed by counting tooth cementum annuli) were used in this study. A classification system of 1-4 was used to record the condition of each of the 3 angles studied. Class 1 status had no physical flaws which could impair the measurement of the given angle. Class 2 status was not flawless but capable of a non-impaired mea-

surement. Class 3 status was very chewed and/or deteriorated to the point where angle measurement may be impaired. Class 4 status was when measurement was not attainable for the given angle due to extreme chewing and/or deterioration.

Angle 1 was measured with a viewing device we constructed that would standardize the perspective and distance of the observer. The device was clamped level onto the ventral side of the pubic symphysis. We then sighted perpendicular to the plane created by the pubic symphysis with the vertex at the intersection of the ischiatic arch and pubic symphysis (Fig. 3). A 152.4 mm (6.0 in) diameter cut-out center 180° protractor was used on this vertex, and the angle measured to the point of first contact with the ischiatic arch on either side of the vertex.

Angle 2 was measured with a 406.4 mm

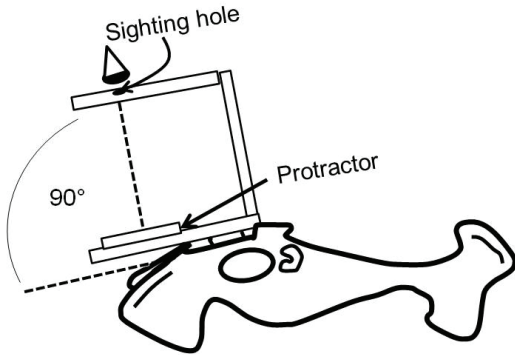


Fig. 3. Proper use of the angle 1 device on moose pelvis (lateral view).

(16.0 in) graduated shape-retaining flexcurve ruler. The ruler was pressed into the inside of the lesser sciatic notch of the pelvis, then removed for measurement. The shape obtained was traced onto paper and the vertex of the created hyperbola found. Using the protractor, vectors of 53.98 mm (2.125 in) and 76.2 mm (3.0 in) were drawn from the vertex out to the point of first contact. The different side lengths for each angle were measured to help ensure angle differences between male and female pelvises were not missed or misrepresented due to selection of an arbitrary vector length (Fig. 4). Angle 3 was measured similarly as angle 2, the only difference being that the graduated flexcurve ruler was pressed into the pelvic brim located on the anterior portion of the pelvis.

The 3 length measurements were 1) total length, 2) length of the pubic symphysis, and 3) outside width at the lesser sciatic notch. Total length measurements were unattainable in most pelvises as a result of wolf chewing to the anterior and/or posterior portions of the pelvis. When possible, total length was measured from the furthest anterior edge of the iliac crest to the furthest posterior edge of the ischium. On all pelvises the length of the pubic symphysis and outside width of the lesser sciatic notch were measured with calipers (no chewing or deterioration was usually present in these areas).

After measuring angles 1, 2, 3, and the 3

lengths, the sample was mixed with others and the process repeated again to evaluate measurement error. Afterward, a random sub-sample was taken and measured by persons other than the primary researcher. These persons had no access to the sex or previous measurements of the moose pelvises. This was done to evaluate inter-observer measurement error.

RESULTS

The angle measuring procedure (including inter-observer measurements) proved to be repeatable to within $\pm 5^\circ$ on all angles with the majority being $\pm 2^\circ$. All 5 normally distributed angular measurements were higher in females than males based on two-tailed t-tests ($P < 0.05$, Table 1). However, only angle 1 allowed unambiguous identification of sex (Fig. 5). Two of the 3 linear measurements (total length and length of the pubic symphysis) were longer in males than females based on two-tailed t-tests ($P < 0.05$, Table 1). The width at the lesser sciatic notch was not different between sexes (male mean = 141.78 mm, female mean = 142.17 mm, $P = 0.8065$, Table 1).

No differences ($P > 0.05$) were found between the 5 angular measurements by the primary researcher (observer 1) and all other observers (observer 2) on male and

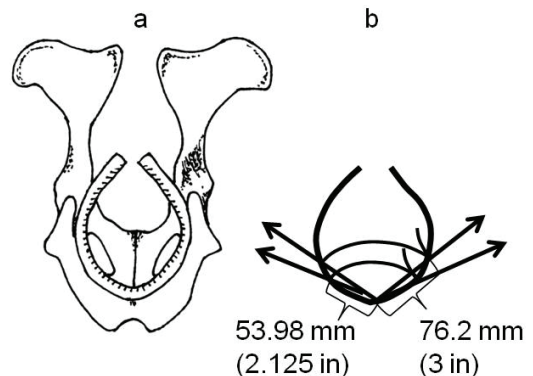


Fig. 4. (a) Measuring angle 2 on an Isle Royale moose pelvis using the graduated flexcurve ruler formed to the inside of the lesser sciatic notch of the pelvis. (b) Outlined sciatic notch with 53.98 mm (2.125 in) and 76.2 mm (3 in) sides drawn to form measurable angles.

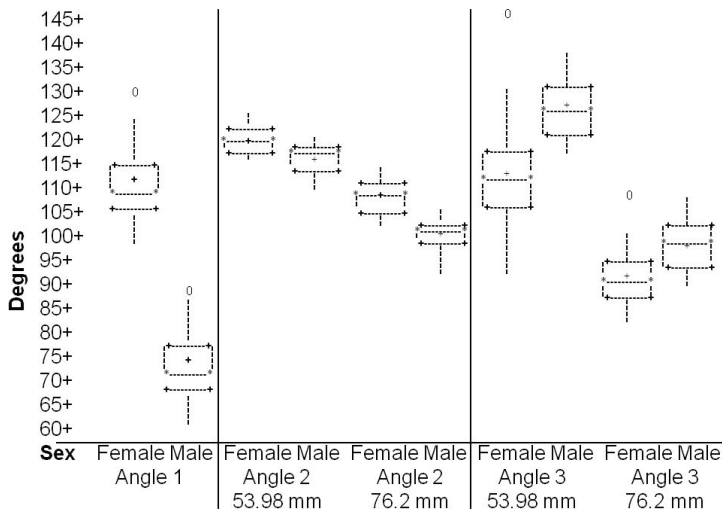


Fig. 5. Box plot data depicting the minimum, lower quartile, median, upper quartile, and maximum numerical values for angles 1, 2 (53.98 mm/76.2 mm) and 3 (53.98 mm/76.2 mm) in Isle Royale moose. The different vector lengths for angles 2 and 3 created 4 measurements each, and were measured to help ensure angle differences between male and female pelvises were not missed or misrepresented due to selection of an arbitrary length.

female pelvises ($n = 16$, Table 2). Only the sub-sample of pelvises measured by persons (collectively termed observer 2) other than the primary researcher was compared against those measurements collected on the same pelvises by observer 1.

DISCUSSION

The angular data collected on pelvis morphology indicated that differences exist between the sexes (Table 1). Angle 1 was the best measurement because no overlap existed between the 15 male and 14 female pelvises sampled (Fig. 5); there was 11° of separation between the largest male and smallest female measurement. Although angles 2 and 3 were significantly different between sexes (Table 1), both had overlapping data

ranges.

Although total length and length of pubic symphysis were significantly different between males and females, there was enough overlap to create uncertainty (one-third overlapped in total length and two-thirds overlapped in length of pubic symphysis). Total length was not measurable in most pelvises due to deterioration from feeding/scavenging animals. Overall, linear pelvic data were ineffective in distinguishing sex of a moose.

Measurement error was not problematic despite the complexity of the angular measurements. The angle of the ischiatic arch (angle 1)

was the only measurement that definitively identified the sex of an unknown moose. As a rule of thumb, males and females exhibit an ischiatic arch angle of $<90^\circ$ and $>90^\circ$, respectively.

Angle 1, the ischiatic arch (the most robust sexing technique of the study) was measured with a device that appears cumbersome and

Table 1. Summary of means for 5 angular and 3 linear measurements of pelvis morphology for Isle Royale moose (17 M:18 F). *P*-value was determined from a *t*-test of null hypothesis that the sexes had the same pelvis morphology.

	Male \pm SE	Female \pm SE	<i>P</i> -value
Angle 1	67.63 \pm 1.51	107.50 \pm 1.49	<0.0001
Angle 2 (53.98 mm)	114.62 \pm 0.75	118.83 \pm 0.78	0.0004
Angle 2 (76.20 mm)	100.21 \pm 0.65	106.19 \pm 0.67	<0.0001
Angle 3 (53.98 mm)	124.83 \pm 1.51	111.92 \pm 1.98	0.0026
Angle 3 (76.20 mm)	97.60 \pm 0.99	90.28 \pm 1.11	0.0015
Total length (mm)	473.88 \pm 3.79	450.83 \pm 5.62	0.0041
Width at lesser sciatic notch (mm)	141.78 \pm 1.10	142.17 \pm 1.12	0.8065
Length of pubic symphysis (mm)	159.38 \pm 0.93	153.00 \pm 1.01	0.0000

Table 2. Summary mean data and their comparison by observer for 5 angular measurements of pelvis morphology in Isle Royale moose performed to test for inter-observer measurement error (see text). The *P*-value was determined from a *t*-test of the null hypothesis that there was no inter-observer measurement error or difference.

	Male Means			Female Means		
	Observer 1	Observer 2	<i>P</i> -value	Observer 1	Observer 2	<i>P</i> -value
Angle 1	72.25	70.83	0.7968	106.42	107.75	0.7943
Angle 2 (53.98 mm)	115.08	116.17	0.4945	118.57	119.00	0.7882
Angle 2 (76.20 mm)	100.70	101.80	0.5552	106.96	107.07	0.9734
Angle 3 (53.98 mm)	126.33	130.00	0.4518	117.56	120.50	0.6667
Angle 3 (76.20 mm)	98.65	100.20	0.6391	92.19	94.00	0.6553

difficult to use without proper instruction. We believe that easier and more accurate methods to measure the ischiatic arch angle are possible, and increased use of this measurement will yield such improvements. That said, with training the current measurement is applicable for field research because it is practical to employ in the field.

Identifying new (non-skull) sexing techniques of skeletal remains, specifically headless, scavenged, or partial carcasses, will benefit wildlife, forensic, archeological, and anatomical studies. We expect that these angular measurements are applicable to other moose populations, the length measurements less so. Regardless, we have identified a simple pelvic measurement to distinguish between male and female moose that has a variety of applications in research, management, and forensics.

ACKNOWLEDGMENTS

The authors would like to thank Isle Royale National Park (Co-op Agreement No. CA-6310-9-8001), the National Science Foundation (DEB-9903671), and Noe Marymor (Natural Resources Conservation Service Private Lands Biologist) for their help and support.

REFERENCES

- BONE, J. F. 1988. *Animal Anatomy and Physiology*. 3rd edition. Prentice-Hall, Inc. Englewood Cliffs, New Jersey, USA.
- DYCE, K. M., W. O. SACK, and C. J. G. WENSING. 2002. *Textbook of Veterinary Anatomy*. 3rd edition. Saunders, Inc. Philadelphia, Pennsylvania, USA.
- EDELMANN, R. H. 1943. *Textbook of Meat Hygiene*. 8th revised edition. Lea and Febiger. Philadelphia, Pennsylvania, USA.
- PETERSON, R. O. 1977. *Wolf Ecology and Prey Relationships on Isle Royale*. Scientific Monographs Series No. 11, U.S. National Park Service, Washington, D. C., USA.
- TABER, R. D. 1956. Characteristics of the pelvic girdle in relation to sex in black-tailed and white-tailed deer. *California Fish and Game* 42: 15-21.
- TODD, T. W., and A. W. TODD. 1938. The epiphysial union pattern of the ungulates with a note on Sirenia. *American Journal of Anatomy*. 63: 1-36.